

## Report

# Grouping of Multiple-Lentigines/LEOPARD and Noonan Syndromes on the *PTPN11* Gene

Maria Cristina Digilio,<sup>1</sup> Emanuela Conti,<sup>2</sup> Anna Sarkozy,<sup>2,3</sup> Rita Mingarelli,<sup>2</sup> Tania Dottorini,<sup>2</sup> Bruno Marino,<sup>4</sup> Antonio Pizzuti,<sup>2,3</sup> and Bruno Dallapiccola<sup>2,3</sup>

<sup>1</sup>Division of Medical Genetics, Bambino Gesù Hospital, Istituto di Ricovero e Cura a Carattere Scientifico, <sup>2</sup>Casa Sollievo della Sofferenza Hospital, Istituto di Ricovero e Cura a Carattere Scientifico, San Giovanni Rotondo and Casa Sollievo della Sofferenza–Mendel Institute, <sup>3</sup>Section of Medical Genetics, Department of Experimental Medicine and Pathology, and <sup>4</sup>Division of Pediatric Cardiology, Institute of Pediatrics, University “La Sapienza,” Rome

**Multiple-lentigines (ML)/LEOPARD (multiple lentigines, electrocardiographic-conduction abnormalities, ocular hypertelorism, pulmonary stenosis, abnormal genitalia, retardation of growth, and sensorineural deafness) syndrome is an autosomal dominant condition—characterized by lentigines and café au lait spots, facial anomalies, cardiac defects—that shares several clinical features with Noonan syndrome (NS). We screened nine patients with ML/LEOPARD syndrome (including a mother-daughter pair) and two children with NS who had multiple café au lait spots, for mutations in the NS gene, *PTPN11*, and found, in 10 of 11 patients, one of two new missense mutations, in exon 7 or exon 12. Both mutations affect the *PTPN11* phosphotyrosine phosphatase domain, which is involved in <30% of the NS *PTPN11* mutations. The study demonstrates that ML/LEOPARD syndrome and NS are allelic disorders. The detected mutations suggest that distinct molecular and pathogenetic mechanisms cause the peculiar cutaneous manifestations of the ML/LEOPARD-syndrome subtype of NS.**

Multiple-lentigines (ML)/LEOPARD (multiple lentigines, electrocardiographic-conduction abnormalities, ocular hypertelorism, pulmonary stenosis, abnormal genitalia, retardation of growth, sensorineural deafness) syndrome (MIM \*151100) is an autosomal dominant condition characterized by ML, electrocardiographic-conduction abnormalities, ocular hypertelorism/obstructive cardiomyopathy, pulmonary stenosis, abnormalities of genitalia in males, retardation of growth, and deafness. This group of characteristics was established as a distinct disorder in 1969 (Gorlin et al. 1969). The diagnostic criteria include ML plus two other recognized features or a first-degree relative with ML plus three other features in the patient (Voron et al. 1976). Several clinical manifestations of ML/LEOPARD syndrome overlap those of Noonan syndrome (NS [MIM #163950]), including facial anomalies, distinct congenital heart de-

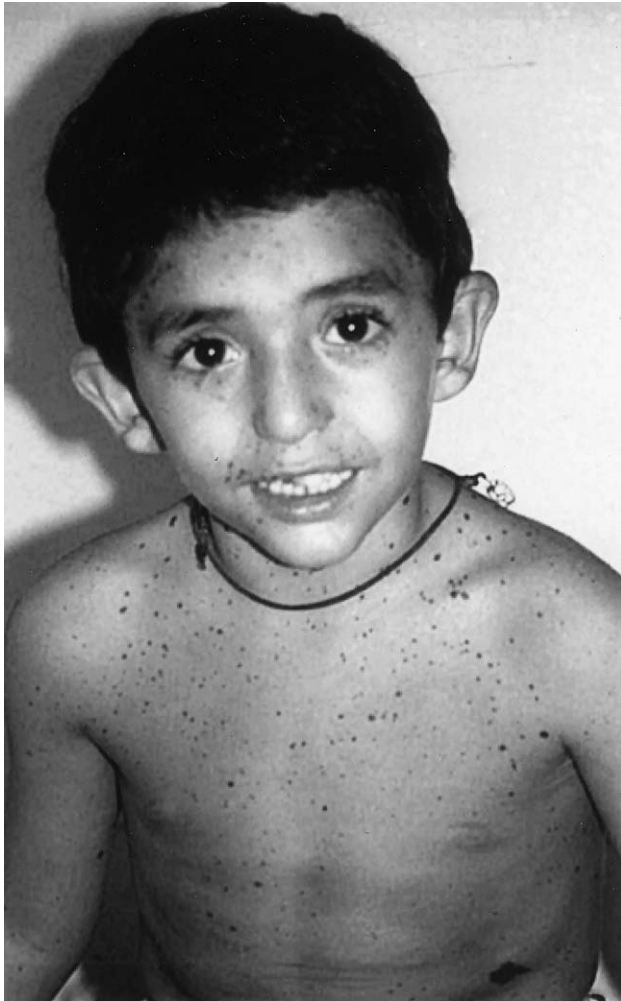fects, pectus deformities, hearing loss, and growth retardation (Blienden et al. 1983; Gorlin et al. 1990; Coppin and Temple 1997). Skin pigmentary changes have been described in both disorders. NS often manifests with pigmented nevi and café au lait spots, whereas ML/LEOPARD syndrome manifests with café au lait spots in early infancy and generalized ML after 5–6 years of age (fig. 1) (Gorlin et al. 1990).

Mutations in *PTPN11* (MIM \*176876), a gene encoding the protein tyrosine phosphatase SHP-2 located at chromosome 12q22-qter (Jamieson et al. 1994), have been identified in a series of NS patients (Tartaglia et al. 2001). We screened for *PTPN11* mutations in nine patients with ML/LEOPARD syndrome, including a mother-daughter pair. We also screened for mutations two 3- and 5-year-old children with features of NS and multiple café au lait spots. Because of their early age, we suspected that these two patients, having not yet developed lentigines, could be regarded as representing examples of early-onset ML/LEOPARD syndrome. The criteria of Voron et al. (1976) were used for the clinical diagnosis of ML/LEOPARD syndrome. The present series was composed of seven female patients and four male patients. Their ages ranged between 3 and 39 years (mean age  $\pm$  SD 11.45  $\pm$

Received March 27, 2002; accepted for publication April 30, 2002; electronically published June 7, 2002.

Address for correspondence and reprints: Dr. Antonio Pizzuti, Istituto CSS-Mendel, Viale Regina Margherita 261, 00198 Rome, Italy. E-mail: a.pizzuti@css-mendel.it

© 2002 by The American Society of Human Genetics. All rights reserved. 0002-9297/2002/7102-0017\$15.00



**Figure 1** Facial appearance of patient 2

10.02 years). Two patients (7 and 8) were related (i.e., mother and daughter), and the remaining nine patients were unrelated. Informed consent was obtained from all patients enrolled in the study. Clinical findings in the patients are summarized in table 1.

Mutation screening of *PTPN11* was performed by SSCP analysis and direct sequencing of all 15 exons and their flanking exon-intron junctions. Heterozygous sequence variations were identified in 10 of 11 patients (table 1). A missense mutation (836A→G; Tyr279Cys) in exon 7 was identified in three patients. Another missense mutation (1403C→T; Thr468Met) in exon 12 was found in five unrelated patients and in the mother-daughter pair (fig. 2). Samples from unaffected parents were not available. The 836A→G and 1403C→T variations were not found in 100 random controls, nor were they found in either the series of 87 patients with NS that we studied (unpublished data) or the patients reported by Tartaglia et al. (2001).

The recurrent mutations in exons 7 and 12, encoding portions of the phosphotyrosine phosphatase (PTP) domain suggest that they are quite characteristically related to the NS phenotype with skin manifestations, including diffuse lentiginos (fig. 3). Thr468Met in exon 12 accounts for the 70% of mutations in the present series of patients with ML/LEOPARD syndrome. No mutation in exon 12 was reported in patients with NS, in whom the N-terminal src-homology 2 (N-SH2) domain is affected in two-thirds of cases (fig. 4). Only one-third of NS mutations occur in the PTP domain, which represents 51% of the total protein. Only one NS mutation in exon 7 has previously been reported, in a different position from the Tyr279Cys (Ile282Val) found in ML/LEOPARD syndrome (fig. 4).

In the native protein, the amino acid Thr468 plays a role that is essential to the catalytic activity. It is located in the consensus sequence of the tyrosine-specific protein phosphatase's active site (amino acids 457–469 [VHCSAGIGRTGTF]), which is necessary for Tyr-phosphatase activity. Moreover, in the native enzyme, Thr468 is involved in several hydrogen bonds toward the solvent molecules, thus representing a stabilizing amino acid for the protein. The methionine introduced in this position may determine an overall change within the protein-hydrogen networks, changing the intrinsic structural properties of the catalytic center. Both Tyr279 and Thr468 amino acids are conserved in several related tyrosine phosphatases, suggesting that these residues play a crucial role in the PTP-domain function.

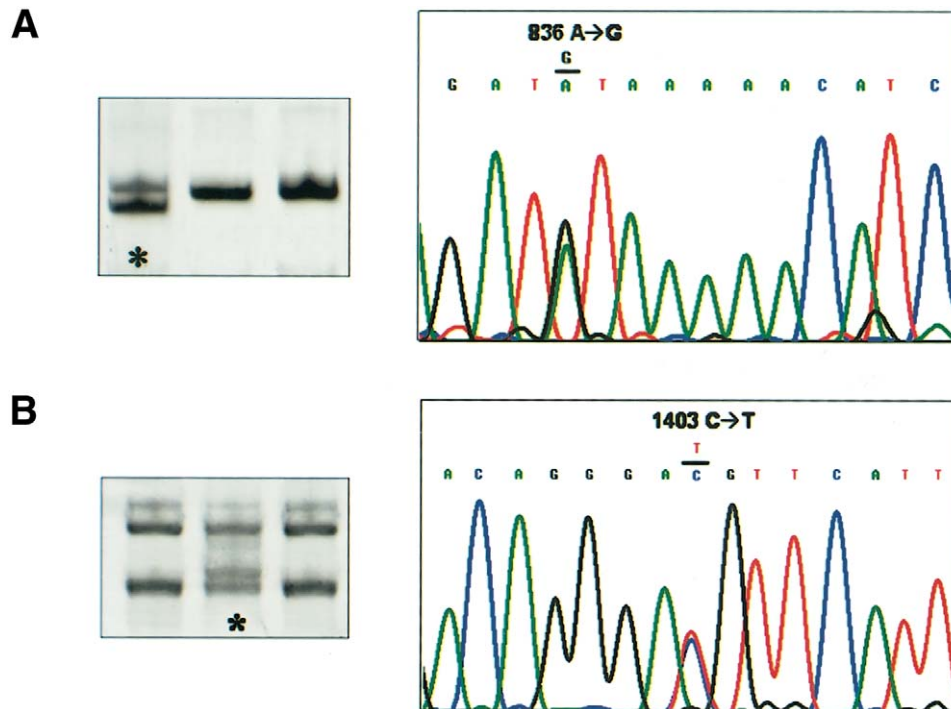
Other syndromes display facial characteristics and cardiac defects that may be superimposed with those of NS, including ML/LEOPARD syndrome, cardiofaciocutaneous syndrome (CFCS [MIM 115150]), neurofibromatosis-Noonan syndrome (NFNS [MIM 601321]), and Costello syndrome (MIM \*218040). However, each of them has some additional features, an observation that fits the idea that they represent clinically distinct disorders. Nevertheless, the tendency to group (or "lump," rather than "split") them was acknowledged elsewhere (Mendez and Opitz 1985; Noonan 1999). For example, NS and CFCS have been considered, on the basis of the analysis of an extended pedigree in which individuals who presented with either condition coexisted, as different manifestations of a unique disorder (Legius et al. 1998). ML/LEOPARD syndrome and NS share facial anomalies (Gorlin et al. 1990) and congenital heart defects, including valvular pulmonary stenosis and hypertrophic obstructive cardiomyopathy (Coppin and Temple 1997; Marino et al. 1999). Interestingly, one of the patients whom we studied had partial atrioventricular canal, which occurs in ~15% of children with NS (Marino et al. 1999). On the contrary, electrocardiographic-conduction anomalies are characteristic of ML/LEOPARD syndrome. Deafness not only may be present in

**Table 1**

**Clinical Findings and Molecular Results in Patients from the Present Series**

CLINICAL FEATURES	OBSERVATIONS IN PATIENT <sup>a</sup>										
	1	2	3	4	5	6	7	8	9	10	11
Sex	M	M	F	F	M	F	F	F	F	M	F
Age (years)	4.8	5.7	9.1	12.8	15	15.1	39	8.9	3	4.9	7.7
ML	+	+	+	+	+	+	+	+	-	-	+
Café au lait spots	-	2	-	10	4	8	4	3	5	15	6
Short stature (<3d percentile)	-	-	+	+	-	-	-	-	-	-	-
Macrocephaly (>75th percentile)	+	+	+	+	+	+	+	+	+	+	+
Facial anomalies:	+	+	+	+	+	+	+	+	+	+	+
Hypertelorism	+	+	+	+	+	+	+	+	+	+	+
Ptosis	+	+	+	-	+	+	+	+	-	+	+
Posteriorly rotated dysmorphic ears	+	+	+	+	+	+	+	+	+	+	+
Cardiovascular anomalies:	+	+	+	-	+	+	-	+	+	+	+
Cardiac defects	PS	HOCM	-	-	AVCD	-	-	MVP	PS, HOCM	HOCM, SubAo	PS
Arrhythmia	-	-	AE	-	-	VE/SVE	-	-	-	-	-
Sternal anomalies	-	+	-	-	+	-	+	+	+	+	+
Deafness	-	-	-	-	-	-	-	-	-	-	+
Undescended testes	-	+	...	...	-	...	...	...	...	-	...
Mental retardation	-	-	-	-	-	-	+	+	-	-	-
Mutation screening:											
<i>PTPN11</i> mutation	49	+	+	+	+	+	+	+	+	+	-
Exon	7	7	7	12	12	12	12	12	12	12	...
Nucleotide substitution	386A→G	386A→G	386A→G	1403C→T	1403C→T	1403C→T	1403C→T	1403C→T	1403C→T	1403C→T	...
Amino acid substitution	Tyr279Cys	Tyr279Cys	Tyr279Cys	Thr468Met	Thr468Met	Thr468Met	Thr468Met	Thr468Met	Thr468Met	Thr468Met	...

<sup>a</sup> Patients 1–8 and 11 have ML/LEOPARD syndrome; patients 9 and 10 have NS with café au lait spots. AE = atrial ectopics; AVCD = atrioventricular canal defect; HOCM = hypertrophic obstructive cardiomyopathy; MVP = mitral valve prolapse; PS = pulmonary stenosis; SubAo = subaortic; SVE = supra-ventricular ectopics; VE = ventricular ectopics; + = feature present; - = feature absent.

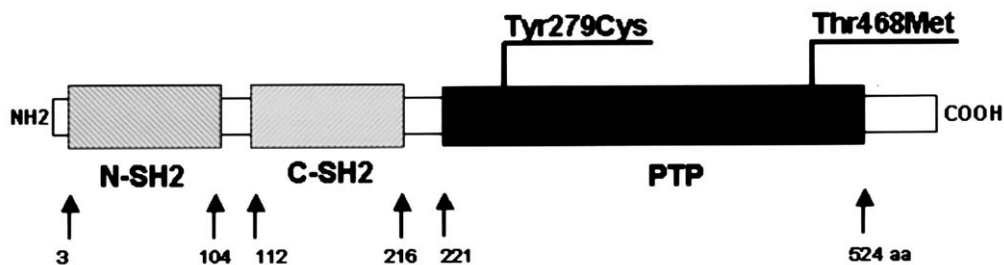


**Figure 2** SSCP and sequence analysis of the two identified mutations. Anomalous patterns of DNA SSCP in patients with ML/LEOPARD syndrome are indicated by asterisks (\*). *a*, Mutation 836A→G in exon 7. *b*, Mutation 1403C→T in exon 12.

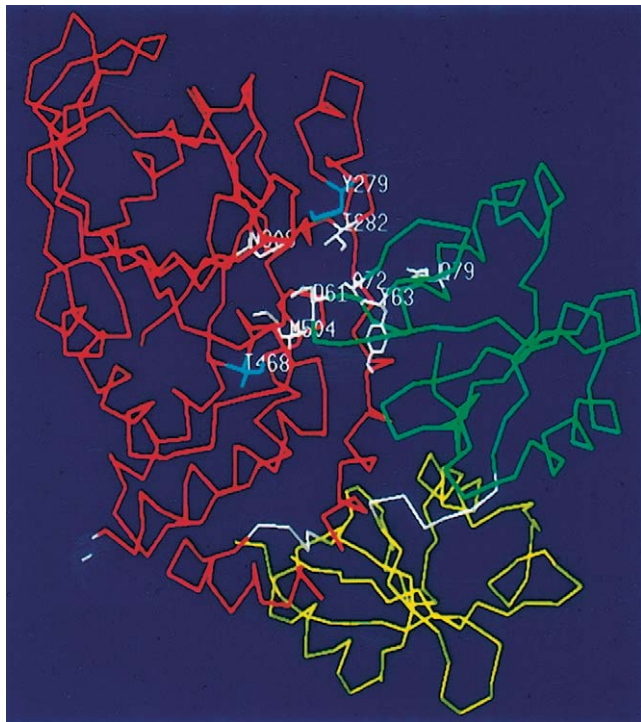
children with ML/LEOPARD syndrome but also may manifest in patients of advanced age, possibly accounting for the normal hearing function in the present series of pediatric patients.

Diffuse lentiginosis is a distinct characteristic of ML/LEOPARD syndrome (fig. 1). Lentigines are rarely present at birth and, classically, develop during childhood, increasing in number until puberty and darkening with age. Café au lait spots often herald the appearance of ML (fig. 1). Both café au lait spots and lentigines are also reported in 10% of patients with NS (Allanson 1987). The exon 12 mutation, which seems to be related to the full-blown

phenotype of ML/LEOPARD syndrome, was also found in two patients with NS that was associated with multiple large café au lait spots. Both these children were <5 years old at the time of evaluation. Thus, it is not possible to predict whether they will develop the ML phenotype later in life or whether they will maintain the NS phenotype with prominent skin features. Watson syndrome (MIM #193520)—characterized by valvular pulmonary stenosis, short stature, mild mental retardation, and café au lait spots (Watson 1967)—also overlaps with NS, ML/LEOPARD syndrome, and neurofibromatosis type 1 (NF1 [MIM \*162200]). Mutations in the neurofibromin



**Figure 3** PTPN11 protein structure and location of the two missense mutations reported. N-SH2 and C-SH2 are the N-terminal and C-terminal tandemly arranged SH2 domains, followed by a protein PTP domain at the C-terminus, where the two mutational hotspots are localized. Functional domains' amino acid boundaries are indicated.



**Figure 4** Structure of PTPN11 protein representation with mutated amino acids.  $\alpha$ -traces of the N-SH2 (green), C-SH2 (clear green), and PTP (red) domains are shown. Mutated residues are indicated by thick lines. Most mutations (thick, white lines) in patients with NS who have been described elsewhere (Tartaglia et al. 2001) are located in the N-SH2 domain. The ML/LEOPARD mutations (thick, cyan lines) are located in the PTP domain. This model was made by use of the program Deep View Swiss-PdbViewer.

gene (*NF1*) have been reported in patients with Watson syndrome (Tassabehji et al. 1993), confirming that this disorder is allelic to *NF1*. However, genetic heterogeneity cannot be excluded, since no linkage with *NF1* was reported in another family with Watson syndrome (Ahlbom et al. 1995).

In the present series of patients with ML/LEOPARD syndrome, a mutation in *PTPN11* was found in all but one patient, suggesting genetic heterogeneity. In patients who had lentigines that were not related to NS, the diagnosis of *NF1* should be considered, since a mutation of the *NF1* gene was found in a woman said to be affected by ML/LEOPARD syndrome (Wu et al. 1996); it should be noted, however, that the diagnosis of ML/LEOPARD syndrome was doubtful, and the *NF1* missense mutation was of uncertain pathological significance. Therefore, molecular studies may be warranted, to test other syndromes with ML (Pipkin and Pipkin 1950; Docu et al. 1976; Carney et al. 1986; Schievink et al. 1995) for *PTPN11* mutations.

In conclusion, the present study demonstrates that *PTPN11* mutations cause ML/LEOPARD syndrome in

addition to the classical NS. The mutations detected in the present series of patients suggest that specific molecular and pathogenetic mechanisms are the cause of the peculiar cutaneous manifestations of the ML/LEOPARD-syndrome subtype of NS.

## Acknowledgments

The present study was supported, in part, by grants from the Italian Ministry of Health and Education. We thank Nicoletta Grifone, Caterina Tandoi, and Giorgia Esposito for technical support.

## Electronic-Database Information

Accession numbers and URLs for data presented herein are as follows:

Deep View Swiss-PdbViewer, <http://www.expasy.ch/spdbv/>  
 Online Mendelian Inheritance in Man (OMIM), <http://www.ncbi.nlm.nih.gov/Omim/> (for ML/LEOPARD syndrome [MIM #151100], NS [MIM #163950], *PTPN11* [MIM \*176876], CFCS [MIM 115150], NFNS [MIM 601321], Costello syndrome [MIM \*218040], Watson syndrome [MIM #193520], and *NF1* [MIM \*162200])

## References

- Ahlbom EB, Dahl N, Zetterqvist P, Anneren G (1995) Noonan syndrome with café-au-lait spots and multiple lentigines syndrome are not linked to neurofibromatosis type 1 locus. *Clin Genet* 48:85–89
- Allanson JE (1987) Noonan syndrome. *J Med Genet* 24:9–13
- Blienden LC, Schneeweiss A, Shem-Tov A, Feigel A, Neufeld HN (1983) Unifying link between Noonan's and Leopard syndromes? *Pediatr Cardiol* 4:168–169
- Carney JA, Headington JT, Su WPD (1986) Cutaneous myxomas: a major component of the complex of myxomas, spotty pigmentation, and endocrine overactivity. *Arch Dermatol* 122:790–798
- Coppin BD, Temple IK (1997) Multiple lentigines syndrome (LEOPARD syndrome or progressive cardiomyopathic lentiginosis). *J Med Genet* 34:582–586
- Docu I, Galaction-Nitelea O, Sirjita N, Murgu V (1976) Centrofacial lentiginosis. *Br J Dermatol* 94:39–43
- Gorlin JR, Cohen MM, Levin LS (1990) Syndromes affecting the skin and mucosa. In: Gorlin JR, Cohen MM, Levin LS (eds) *Syndromes of the head and neck*. Oxford University Press, New York, pp 461–464
- Gorlin RJ, Anderson RC, Blaw M (1969) Multiple lentigines syndrome. *Am J Dis Child* 117:652–662
- Jamieson CR, van der Burgt I, Brady AF, van Reen M, Elsalw MM, Hol F, Jeffery S, Patton MA, Mariman E (1994) Mapping a gene for Noonan syndrome to the long arm of chromosome 12. *Nat Genet* 8:357–360
- Legius E, Schollen E, Matthijs G, Fryns JP (1998) Fine mapping of Noonan/cardio-facio-cutaneous syndrome in a large family. *Eur J Hum Genet* 6:32–37
- Marino B, Digilio MC, Toscano A, Giannotti A, Dallapiccola

- B (1999) Congenital heart diseases in children with Noonan syndrome: an expanded cardiac spectrum with high prevalence of atrioventricular canal. *J Pediatr* 135:703–706
- Mendez HMM, Opitz JM (1985) Noonan syndrome: a review. *Am J Med Genet* 21:493–506
- Noonan JA (1999) Noonan syndrome revisited. *J Pediatr* 135:667–668
- Pipkin AC, Pipkin SB (1950) A pedigree of generalised lentigo. *J Hered* 41:79–82
- Schievink WI, Michels VV, Mokri B, Piepgras DG, Perry HO (1995) A familial syndrome of arterial dissections with lentiginosis. *New Engl J Med* 332:576–579
- Tartaglia M, Mehler EL, Goldberg R, Zampino G, Brunner HG, Kremer H, van der Burgt I, Crosby AH, Ion A, Jeffery S, Kalidas K, Patton MA, Kucherlapati RS, Gelb BD (2001) Mutations in *PTPN11*, encoding the protein tyrosine phosphatase SHP-2, cause Noonan syndrome. *Nat Genet* 29:465–468
- Tassabehji M, Strachan T, Sharland M, Colley A, Donnai D, Harris R, Thakker N (1993) Tandem duplication within a neurofibromatosis type I (NF1) gene exon in family with features of Watson syndrome and Noonan syndrome. *Am J Hum Genet* 53:90–95
- Voron DA, Hatfield HH, Kalkhoff MD (1976) Multiple lentiginos syndrome: case report and review of the literature. *Am J Med* 60:447–456
- Watson GH (1967) Pulmonary stenosis, café-au-lait spots, and dull intelligence. *Arch Dis Child* 42:303–307
- Wu R, Legius E, Robberecht W, Dumoulin M, Cassiman JJ, Fryns JP (1996) Neurofibromatosis type I gene mutation in a patient with features of LEOPARD syndrome. *Hum Mutat* 8:51–56